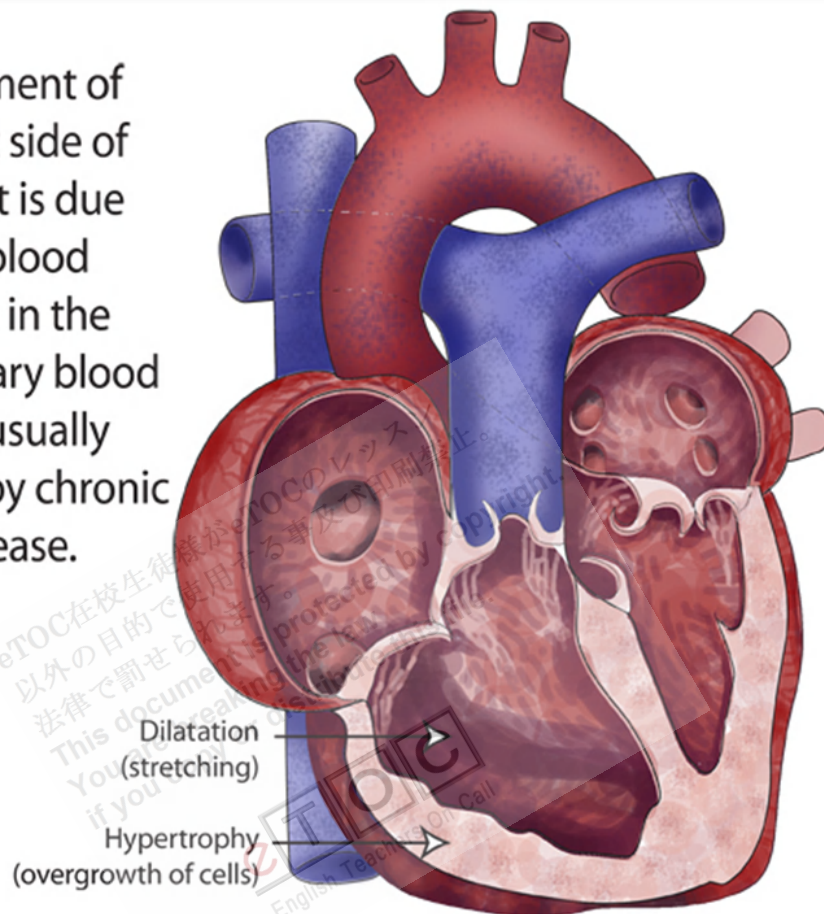


Cor Pulmonale

Enlargement of the right side of the heart is due to high blood pressure in the pulmonary blood vessels, usually caused by chronic lung disease.



<http://mbbsdost.com/fbapp/medi-notes/images/other-article-Medicine-19-April-2012-09-11-030.png>

Cor pulmonale is right ventricular enlargement secondary to a lung disorder that causes pulmonary artery hypertension. Right ventricular failure follows. Findings include peripheral edema, neck vein **distention**, **hepatomegaly**, and a **parasternal lift**. Diagnosis is clinical and by echocardiography. Treatment is directed at the cause.

Cor pulmonale results from a disorder of the lung or its **vasculature**; it does not refer to right ventricular (RV) enlargement secondary to left ventricular (LV) failure, a congenital heart disorder (eg, **ventricular septal defect**), or an acquired valvular disorder. Cor pulmonale is usually chronic but may be acute and **reversible**. Primary pulmonary

hypertension (ie, not caused by a pulmonary or cardiac disorder) is discussed elsewhere.

Pathophysiology

Lung disorders cause pulmonary hypertension by several mechanisms:

- Loss of capillary beds (eg, due to bullous changes in COPD or thrombosis in pulmonary embolism)
- Vasoconstriction caused by **hypoxia**, **hypercapnia**, or both
- Increased alveolar pressure (eg, in COPD, during mechanical ventilation)
- Medial hypertrophy in arterioles (often a response to pulmonary hypertension due to other mechanisms)

Pulmonary hypertension increases afterload on the RV, resulting in a **cascade** of events that is similar to what occurs in LV failure, including elevated end-diastolic and central venous pressure and ventricular hypertrophy and **dilation**. Demands on the RV may be intensified by increased blood **viscosity** due to hypoxia-induced **polycythemia**. Rarely, RV failure affects the LV if a dysfunctional septum bulges into the LV, interfering with filling and thus causing diastolic dysfunction.

Etiology

Acute cor pulmonale has few causes. Chronic cor pulmonale is usually caused by COPD, but there are several less common causes. In patients with COPD, an acute exacerbation or pulmonary infection may trigger RV overload. In chronic cor pulmonale, risk of **venous thromboembolism** is increased.

Table 3

Causes of Cor Pulmonale	
Acuity	Condition
Acute	Massive pulmonary embolization Injury due to mechanical ventilation (most commonly for ARDS)
Chronic	COPD* Extensive loss of lung

tissue due to surgery or trauma

Chronic, unresolved pulmonary emboli

Pulmonary veno-occlusive disorders

Systemic sclerosis

Pulmonary interstitial fibrosis

Kyphoscoliosis

Obesity with alveolar hypoventilation

Neuromuscular disorders involving respiratory muscles

Idiopathic alveolar hypotension

*COPD is the most common cause of chronic cor pulmonale.
ARDS = acute respiratory distress syndrome.

Symptoms and Signs

Initially, cor pulmonale is asymptomatic, although patients usually have significant symptoms due to the underlying lung disorder (eg, dyspnea, exertional fatigue). Later, as RV pressures increase, physical signs commonly include a left **parasternal systolic lift**, a loud pulmonic component of the 2nd heart sound (S_2), and murmurs of functional **tricuspid** and pulmonic insufficiency. Later, an RV gallop rhythm (3rd [S_3] and 4th [S_4] heart sounds) augmented during inspiration, **distended** jugular veins (with a dominant a wave unless tricuspid regurgitation is present), hepatomegaly, and lower-extremity edema may occur.

Diagnosis

- Clinical suspicion
- Echocardiography

Cor pulmonale should be suspected in all patients with one of its causes. Chest x-rays show RV and proximal pulmonary artery enlargement with distal arterial **attenuation**. ECG evidence of RV hypertrophy (eg, right axis deviation, QR wave in lead V₁, and dominant R wave in leads V₁ to V₃) correlates well with degree of pulmonary hypertension. However, because pulmonary **hyperinflation** and **bullae** in COPD cause realignment of the heart, physical examination, x-rays, and ECG may be relatively insensitive. Echocardiography or radionuclide imaging is done to evaluate LV and RV function; echocardiography can assess RV systolic pressure but is often technically limited by the lung disorder. Right heart catheterization may be required for confirmation.

Treatment

- Treatment of cause

Treatment is difficult; it focuses on the cause (see elsewhere in THE MANUAL), particularly **alleviation** or moderation of hypoxia. Early identification and treatment are important before structural changes become **irreversible**.

If peripheral edema is present, diuretics may seem appropriate, but they are helpful only if LV failure and pulmonary fluid overload are also present; they may be harmful because small decreases in preload often worsen cor pulmonale. Pulmonary vasodilators (eg, hydralazine, Ca channel blockers, nitrous oxide, prostacyclin, phosphodiesterase inhibitors), although beneficial in primary pulmonary hypertension, are not effective. Bosentan, an endothelin receptor blocker, also may benefit patients with primary pulmonary hypertension, but its use is not well studied in cor pulmonale. Digoxin is effective only if patients have concomitant LV dysfunction; caution is required because patients with COPD are sensitive to digoxin's effects. Phlebotomy during hypoxic cor pulmonale has been suggested, but the benefits of decreasing **blood viscosity** are not likely to offset the harm of reducing O₂-carrying capacity unless significant polycythemia is present. For patients with chronic cor pulmonale, long-term **anticoagulants** reduce risk of venous **thromboembolism**.